McKenna was a previously healthy 4-year-old who presented to her primary care physician with a fever of 102 degrees, shallow breathing, loss of appetite, and swollen lymph nodes.

List of differential diagnosis

- Viral illness
- Pneumonia
- Pleuropulmonary blastoma
- Influenza
- Pleural effusion

McKenna at age 5 in February 2007

McKenna at age 7 in 2009

The primary physician prescribed an antibiotic which improved McKenna's condition for two to three weeks. However, McKenna re-presented to her primary physician with complaints of stomach pain, left shoulder pain, vomiting, diarrhea, sore throat, earache, persistent and non-productive cough, and fever of 101 degrees. She was referred to the emergency department for evaluation based upon her exam.

On arrival to the emergency department, McKenna had significantly increased respiratory effort as she could only breathe while laying on her left side. Adequate breath sounds were noted on the right, with absent breath sounds on the left. A chest X-ray was obtained.

Figure (1): Admission CXR, showing large tumor involving the entire left hemithorax and heart shift into the right chest. Note the trachea, arrow, deviated to the right.

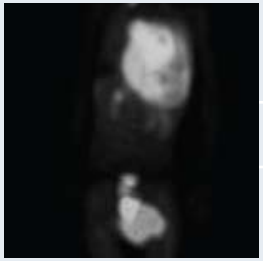

McKenna underwent a CT scan, two biopsies by interventional radiology, and a PET scan, (figure 2), which confirmed the large tumor in the left chest was compressing all of her mediastinal organs.

Figure (2): Initial PET scan showing extensive uptake within the tumor.

The last biopsy on July 12 confirmed left pleural pulmonary blastoma. Due to the large size of the tumor, the recommendation was to treat initially with chemotherapy to shrink the tumor so resection could be safely undertaken.

McKenna was followed with frequent CXRs, (figure 3), CT scans (figure 4) and PET scans, (figure 5) during the chemotherapy treatment.

Figure (3): Regression of tumor on CXR from response to chemotherapy. (a) July 2006, (b) August 2006, (c) January 2007, (d) Post-operative, February 9, 2007 chest tube in left pleural space

Figure (4): Regression of tumor seen on CT scan (a) July 2006, (b) August 2006, (c) February 2007

Figure (5): PET scan January 2007, showing no uptake in the tumor bed.

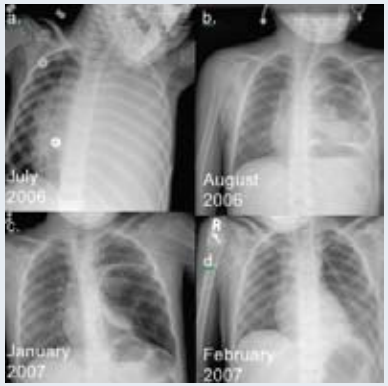

Figure (3)

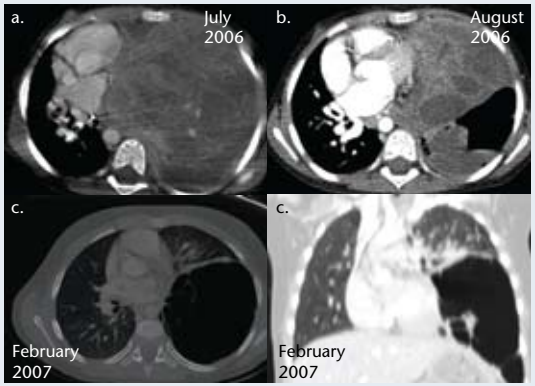

Figure (4)

Figure (5)

After five cycles of chemotherapy, Dr. Phillips performed a left extrapleural pneumonectomy on now 5-year-old McKenna. The goal was to remove the entire tumor with the entire left lung and parietal pleura, called an extrapleural pneumonectomy. The tumor is encased in the pleura and needs to be resected in certain tumors, like this one, to ensure negative margins. During the surgery the tumor was noted to be invading the diaphragm and pericardium, (figure 6), which were both resected en-bloc with the tumor. Both were then reconstructed with GORE-TEX® patches, (figure 7). During surgery and post-operatively there were no complications or difficulties.

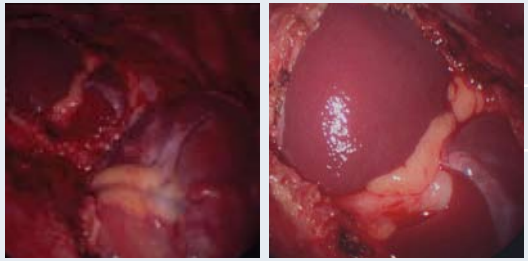

Figure (6): Diaphragm and pericardium resected.

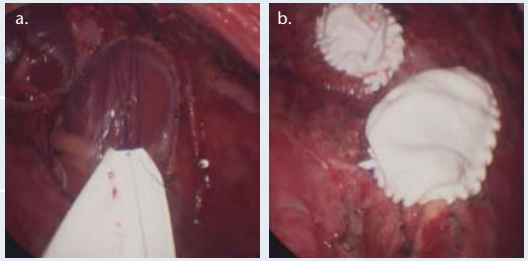

Figure (7): (a) Reconstruction of the pericardium with GORE-TEX® patch and (b) Completed patches of the diaphragm and pericardium.

The pathology revealed that the entire tumor was removed and all margins were negative except one microscopic area which showed tumor going into the margin. She received post-operative chemotherapy which has now been completed. She will need to be followed for the rest of her life, but she has done remarkably well throughout the entire 10 months of her treatment.

Patient Outcome

McKenna's surgeries and treatments are proving successful and she has resumed a normal life for a 7-year-old girl, playing with her friends and going to school. She will continue follow-up therapy for the rest of her life. Her prognosis is excellent.

Case study adapted from article published in *Pediatric Directions*.