NATIONWIDE CHILDREN'S HOSPITAL℠

700 Children's Drive
Columbus, Ohio 43205-2696
nationwidechildrens.org

BRAIN TUMORS

Brain tumors are the most common type of solid tumor that occurs in children. A brain tumor is an abnormal mass or growth. Some are malignant (cancerous) and some may be benign. It results when cells in or around the brain divide excessively. Brain tumors are grouped according to the type of cells where the tumor begins. For example:

- Ependymoma (eh-pen-dee-MOE-mah) starts from cells that line the ventricular system and central canal in the spinal cord.
- Astrocytoma (as-troe-sy-TOE-mah) starts from cells that support the nerve cells.
- Medulloblastoma (med-you-low-blas-TOW-mah) starts from primitive glial-type cells.
- Pinealoma (pin-ee-ah-LOW-mah) starts in the pineal gland.
- Meningioma (men-IN-jee-oh-mah) begins in the meninges – the tissue that lines the brain and spinal cord.
- Glioma (gli-OH-mah) starts in certain nerve cells, called *glial* cells.

DIAGNOSTIC TESTS

Once a brain tumor is suspected, tests are done to locate and diagnose the tumor. A skull X-ray may be done. A computed tomography (CT) scan -a special X-ray that uses a computer- helps to locate the tumor. A magnetic resonance imaging (MRI) scan shows the organs and structures inside the body. Other tests that may be done are an EEG, brain scan, myelogram, or a spinal tap.

A *biopsy* of the brain tumor will also be done if possible. This means removing some of the tumor with surgery. A pathologist then examines the biopsy under a microscope to help identify the type of tumor.

These Helping Hands describe the diagnostic tests your child may have:

- *X-Ray,* HH-III-17
- *CT Scan,* HH-III-19
- *MRI (Magnetic Resonance Imaging),* HH-III-69
- *EEG (Electroencephalogram),* HH-III-5
- *Spinal Tap,* HH-III-21

If you have not received a Helping Hand for your child's test, please ask for one.

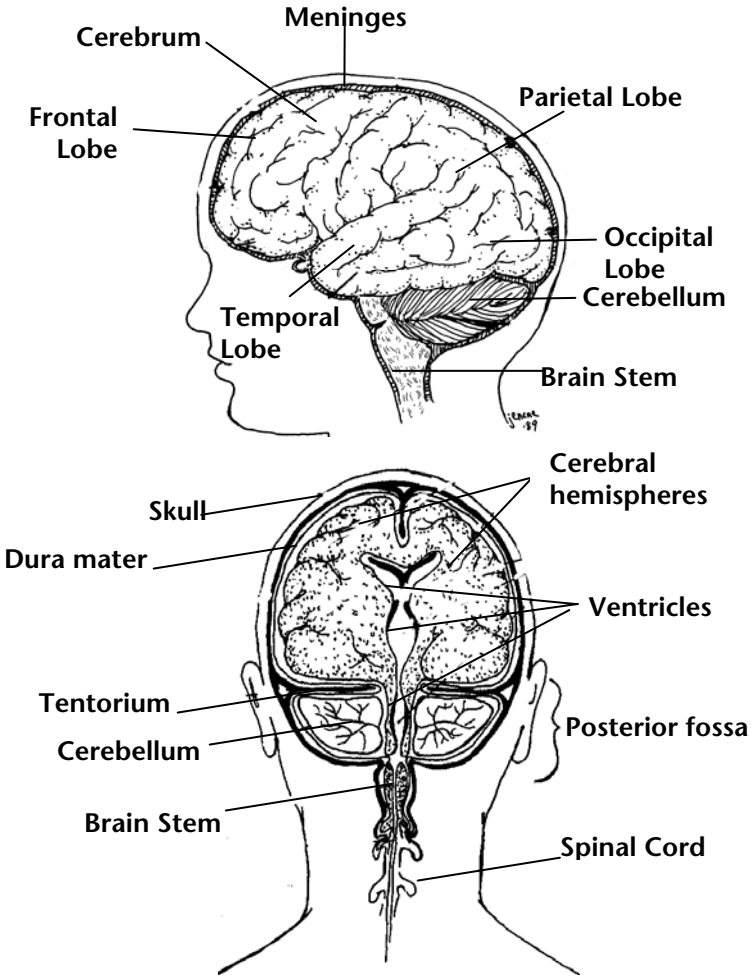

Picture 1 The areas of the brain.

TYPES OF BRAIN TUMORS

Brain tumors are also grouped by the area of the brain where the tumor is located. After the diagnostic tests are complete, the doctors will identify the type of brain tumor and talk with you about the plan of treatment.

Area of the Brain	Signs and Symptoms	Treatment
Cerebellar Tumors (tumors in the cerebellum): These tumors may be benign (non-cancerous) or malignant. Astrocytomas, ependymomas, and medulloblastomas are tumors seen in this area of the brain.	▪ Severe headaches ▪ Vomiting ▪ Increased sleepiness ▪ Lethargy (lack of energy) ▪ Unsteady gait ▪ Difficulty walking	Surgery, radiation, and/or chemotherapy are part of the treatment.
Brain Stem Tumors: Gliomas occur in the brain stem.	▪ Vision changes ▪ Trouble swallowing ▪ Unsteady gait ▪ Difficulty walking ▪ Weakness of arm or leg	Radiation or chemotherapy are part of the treatment. Often surgery to remove the tumor cannot be done because of where the tumor is located. Sometimes a surgical biopsy is done to help with diagnosis.
Cerebral Hemisphere Tumors (tumors in the cerebrum): Gliomas and meningiomas are the most common tumors that involve the cerebral hemispheres of the brain.	▪ Headaches ▪ Seizures ▪ Weakness or paralysis on one side ▪ Trouble speaking ▪ Partial loss of sight ▪ Changes in personality, intellect, or level of consciousness.	Surgery, radiation, and chemotherapy are part of the treatment, depending on the type of tumor.
Sellar and Parasellar Tumors: Optic gliomas and craniopharyngiomas (CRAY-nee-oh-fair-in-gee-OH-ma) are found most often in children. Craniopharyngioma is a non-cancerous tumor. It involves the pituitary gland, hypothalamus, and visual system.	▪ Loss of vision ▪ Headache ▪ Short stature (child is short for age)	Radiation or surgery are part of the treatment. Chemotherapy may be part of the treatment.
Pineal Region Tumors: These tumors may be cancerous or non-cancerous. Germinomas, pinealomas, teratomas, astrocytomas, and meningiomas are located in this area of the brain.	▪ Headache ▪ Vomiting ▪ Vision changes ▪ Lethargy (lack of energy)	Surgery, radiation, or chemotherapy are part of the treatment, depending on the type of tumor.

BRAIN TUMOR TERMS

The information on pages 3 and 4 is to help you understand words that you may hear that are used to describe a brain tumor.

GENERAL TERMS

Benign (be-NINE) - noncancerous cells, not malignant.

Malignant (mah-LIG-nent) - made up of cancerous cells. The word "malignant" may also refer to a benign tumor that is located in a vital area of the brain.

Metastasis (mah-TASS-ta-sis) – when a tumor spreads or grows.

Primary tumor - a tumor that grew in the brain first, or is found only in the brain. In some cases the tumor cells may have spread to other areas of the body.

Resection - the removal of all or part of the tumor.

Secondary tumor - a tumor that spreads to the brain from tumor cells in another part of the body.

Biopsy (BI-op-see) - a small part of the brain tumor is removed during surgery so it can be examined under a microscope and the cell type can be studied.

TERMS FOR THE EXACT LOCATIONS OF BRAIN TUMORS

Dura mater (DUR-ah ma-ter) - a thick tissue that covers all of the brain and protects it.

Tentorium (ten-TORE-ee-um) - a thick layer of tissue (membrane) that extends from the dura mater. It separates the posterior fossa from the cerebral hemispheres.

Posterior fossa (pos-TEER-ee-or FOSS-ah) - area within the skull which contains the brain stem and cerebellum. It is below the tentorium. Seventy percent of brain tumors in children are found here.

Cerebral hemisphere (seh-REE-bral HEM-is-fear) - area above the tentorium. The right cerebral hemisphere controls the left side of the body. The left cerebral hemisphere controls the right side of the body. Together they are called the cerebrum.

Cerebellum (sa-rah-BELL-um) - two lobes of the brain that help coordinate how your child moves.

Brain stem - bottom-most part of the brain. It connects the cerebral hemisphere with the spinal cord.

Ventricles - fluid-filled hollow areas in the brain.

TERMS FOR THE GENERAL LOCATIONS OF TUMORS

Anterior (an-TEAR-e-or) - toward the front, forward.

Fossa (FOSS-ah) - a low spot or "hollow" in the bone. "Fossa" refers to areas within the skull.

Hyper- (HI-per) - high, over.

Hypo- (HI-poe) - low, under.

Infra- (IN-fra) - below, under.

Para- (PEAR-ah) - beside, next to.

Posterior (pos-TEAR-e-or) - toward the back, behind.

Sella (SELL-ah) - a small, saddle-shaped sunken area of bone behind the nose and eyes.

Sub- under, near.

Supra- (SUE-pra) - above, over.

TERMS FOR THE WAY TUMOR CELLS ARE GROUPED

Cell Differentiation (sell dif-er-en-she-A-shun) - refers to how closely the tumor cells look like normal cells.

Grade I - most like normal cells of the brain tissue. They are usually benign (non-cancerous).

Grade II - somewhat like normal cells of the brain tissue.

Grade III - poorly resemble normal cells of the brain tissue.

Grade IV - very poorly resemble normal brain tissue cells. They are usually malignant (cancerous).