

Isoflurane for Refractory Status Epilepticus: A Clinical Series

W. Andrew Kofke, M.D.,* Richard S. K. Young, M.D.,† Peter Davis, M.D.,‡ Susan K. Woelfel, M.D.,§
Lenore Gray, M.D.,¶ Dean Johnson, M.D.,** Adrian Gelb, M.B.Ch.B., F.R.C.P.(C.),††
Rodney Meeke, M.B.F.F.A.R.C.S.I.,‡‡ David S. Warner, M.D.,§§ Kent S. Pearson, M.D.,§§
Jeff Ray Gibson, Jr., M.D.,¶¶ John Koncinski, D.O.,*** Henry B. Wessel, M.D.†††

General anesthesia has been recommended to control convulsive status epilepticus that is refractory to conventional anticonvulsant therapy. Halothane has been the recommended agent, but without experimental justification. Isoflurane, which has no reported organ toxicity and produces electrographic suppression at clinically useful concentrations in normal humans, should be a better volatile anesthetic for this purpose. The efficacy and safety of isoflurane administered to control convulsive status epilepticus were assessed on 11 occasions in nine patients in seven North American hospitals. Isoflurane, administered for 1-55 h, stopped seizures in all patients and was able to be titrated to produce burst-suppression patterns on electroencephalograms. Blood pressure support with iv fluids and/or pressor infusions was required in all of the patients. Seizures resumed upon discontinuation of isoflurane on eight of 11 occasions. Six of the nine patients died. The three survivors sustained cognitive deficits. In one patient urine fluoride concentrations were elevated, although not to nephrotoxic levels. These cases suggest that isoflurane 1) is an effective, rapidly titratable anticonvulsant; 2) does not reverse underlying causes of the refractory seizures; and 3) usually necessitates hemodynamic support with fluids and/or pressors. Isoflurane may be administered for seizures, but only when iv agents in anesthetic doses are ineffective or produce unacceptable side effects. (Key words: Anesthetics, volatile: isoflurane. Brain: status epilepticus.)

STATUS EPILEPTICUS is defined as "epileptic seizures that are so frequently repeated or so prolonged as to create a fixed and lasting epileptic condition."^{1,2} In clinical practice

this diagnosis usually is given when continuous seizures last 30 min or longer, even when consciousness is not impaired.² Status epilepticus can be classified as follows: 1) generalized convulsive status epilepticus in which the patient remains unconscious between tonic-clonic attacks, 2) nonconvulsive status epilepticus, *e.g.*, absence and complex partial status epilepticus, or 3) continuous partial seizures (epilepsia partialis continua) in which consciousness is maintained.² Partial seizures can be further categorized as having elementary symptomatology without impairment of consciousness (*e.g.*, Jacksonian) or as having complex symptomatology, which may include impairment of consciousness.³ Partial seizures can also generalize secondarily.

Tonic-clonic (convulsive) status epilepticus is a neurologic emergency that should be stopped within 60 min.² After initiation of therapy generalized convulsive status epilepticus may convert to "subtle" status epilepticus, a condition wherein focal convulsive activity persists (*e.g.*, isolated facial or shoulder twitching) with continued electrographic seizure activity and coma.^{†††} When this condition develops, continued aggressive therapy is probably still indicated. General anesthesia has been recommended to control status epilepticus that is refractory to conven-

* Assistant Professor, Departments of Anesthesiology and Critical Care Medicine (Neurologic Anesthesia and Supportive Care Program) and Neurosurgery, University of Pittsburgh School of Medicine (patients 1, 2, and 3).

† Associate Professor, Departments of Pediatrics and Neurology, Yale University School of Medicine (patients 2 and 3).

‡ Assistant Professor, Departments of Anesthesiology and Critical Care Medicine and Pediatrics, University of Pittsburgh School of Medicine (patient 4).

§ Assistant Professor, Department of Anesthesiology and Critical Care Medicine, University of Pittsburgh School of Medicine (patient 4).

¶ Clinical Associate Professor, Department of Neurology, Wright State University School of Medicine (patient 5).

** Clinical Associate Professor, Department of Anesthesiology, Wright State University School of Medicine (patient 5).

†† Associate Professor, Department of Anaesthesia, University of Western Ontario Faculty of Medicine (patient 6).

‡‡ Consultant Anesthetist, Department of Anesthetics, Cork Regional Hospital, Wilton, Cork, Ireland (patient 6).

§§ Assistant Professor, Department of Anesthesia, University of Iowa Hospitals and Clinics (patient 7).

¶¶ Senior Staff Anesthesiologist and Assistant Professor (Surgery), Department of Anesthesiology, Scott & White Clinic and Texas A&M University College of Medicine (patient 8).

*** Assistant Professor, Department of Anesthesiology and Critical Care Medicine, University of Pittsburgh School of Medicine (patient 9).

††† Assistant Professor, Departments of Pediatrics and Neurology, University of Pittsburgh School of Medicine (patients 4 and 9).

Received from Massachusetts General Hospital, Harvard University, Boston, Massachusetts; Milton S. Hershey Medical Center, Pennsylvania State University, Hershey, Pennsylvania; Children's Hospital of Pittsburgh, University of Pittsburgh, Pittsburgh, Pennsylvania; Charles F. Kettering Memorial Hospital, Wright State University, Dayton, Ohio; University Hospital, University of Western Ontario, London, Canada; University of Iowa Hospitals and Clinics, University of Iowa, Iowa City, Iowa; and Scott & White Memorial Hospital, Texas A&M University College of Medicine, Temple, Texas. Accepted for publication June 21, 1989. Supported in part by Anaquest. Presented in part at the meetings of the American Academy of Neurology, New York, New York, 1987; the American Society of Anesthesiologists, Atlanta, Georgia, 1987; and the World Federation of Anesthesiologists, Washington, D.C., 1988.

Address reprint requests to Dr. Kofke: Department of Anesthesia/CCM, University of Pittsburgh School of Medicine, 1385 Scaife Hall, Pittsburgh, Pennsylvania 15261.

††† Treiman DM, DeGiorgio C, Salisbury S, Wickboldt C: Subtle generalized convulsive status epilepticus (abstract). *Epilepsia* 25:653, 1984.

tional anticonvulsant therapy.^{2,3} Although halothane has been the recommended volatile agent,^{2,3} no experimental justification or clinical series has been published to support its use. Halothane can produce a degree of EEG suppression⁴ that would make it a reasonable anesthetic to use in this condition. However, the doses required to produce such EEG suppression have unacceptable hemodynamic side effects, presumably due to systemic vasodilation and negative inotropic effects.⁵ In addition, the degree of biodegradation associated with halothane⁶ and its possible hepatotoxicity, especially in patients with anticonvulsant-mediated hepatic enzyme induction, increase concern regarding prolonged administration. Isoflurane may be a better agent for this use because it can produce EEG suppression at concentrations not ordinarily associated with undesirable hemodynamic effects and because it lacks known organ toxicity.^{4,6-8} In this report we assess the efficacy and safety of isoflurane administered to attenuate convulsive generalized or "subtle" status epilepticus on 11 occasions in nine patients.

Materials and Methods

All patients studied had convulsive generalized status epilepticus or subtle status epilepticus.^{1-3,†††} Information for patients 1 and 4-9 was obtained retrospectively from the records provided by the anesthesiologists who had administered isoflurane. Patients 2 and 3 received isoflurane prospectively after protocol approval by the institutional clinical investigation committee. Patients 1 and 2 have been described previously.^{9,10} In all cases prior to institution of isoflurane therapy, conventional therapy with at least phenobarbital, phenytoin, and benzodiazepines had failed to control seizures, and tracheal intubation had been performed. The following were monitored during isoflurane therapy: intraarterial blood pressure (except patient 4, sphygmomanometer), central venous or pulmonary artery pressure (except patient 9), EKG, and EEG. Anesthetic gas monitoring was used in patients 2, 3, 5, 7, and 8.

Results

In all cases isoflurane administration stopped or substantially attenuated EEG and convulsive seizure activity. In all cases it necessitated fluid administration and/or pressor support. The details of each patient follow (table 1).

Case 1. A 29-yr-old man was admitted after a viral syndrome after presenting at another hospital with generalized tonic-clonic seizures that had progressed to status epilepticus. Convulsions were intermittently controlled with phenytoin, phenobarbital, valproic acid, clonazepam, paraldehyde, carbamazepine, trimethadione, phenacemide, lidocaine, pyridoxine, and adrenocorticotrophic hormone (ACTH). On day 32 with the onset of another episode of convulsive status epilepticus,

the patient was given inhaled isoflurane anesthesia, which stopped convulsive seizures and produced electrocerebral inactivity (recording at 3 μ V/mm) at an inspired concentration of 3%. Mean arterial blood pressure (MAP) was maintained at 75 mmHg with phenylephrine. Isoflurane was administered for 35 min during which time two facial twitches were noted. Discontinuation was followed by additional convulsive seizure activity. Another trial of isoflurane administration was performed on day 40. This trial lasted 5 h, and attenuation of EEG and convulsive seizure activity was attained with 1-1.5% inspired isoflurane. During this time electrocerebral silence was evident (7 μ V/mm gain) except for rare low-voltage bursts and seven brief facial seizures. In the final minutes 70-100 μ V sharp activity occasionally interrupted the background activity. MAP was again supported with phenylephrine (70-80 mmHg). After discontinuation of isoflurane, EEG and convulsive status epilepticus resumed. The patient subsequently was determined to be brain dead on the 52nd hospital day.

Case 2. A 10-yr-old girl presented in generalized convulsive tonic-clonic status epilepticus after a viral illness. Seizures were unsuccessfully treated with phenobarbital, phenytoin, paraldehyde, and diazepam. Three 1-week trials of pentobarbital infusion each controlled convulsive seizure activity and produced EEG suppression. However, each time the rate of pentobarbital infusion was decreased, electrographic seizures resumed in association with facial twitching. On the 27th hospital day isoflurane was administered for seizure control when withdrawal of pentobarbital resulted in resumption of EEG seizures (spike and wave every 1-2 s) with facial twitching. Seizures were attenuated initially at an end-tidal isoflurane concentration of 0.8%, which subsequently was increased to 2.1% to maintain attenuation of seizure bursts. During the 48 h of isoflurane administration, two brief episodes of bilateral leg twitching occurred with nursing procedures. The maximal burst-suppression interval achieved was 1 min. MAP decreased from 115 mmHg (preseizure) to 61-80 mmHg; thereafter blood pressure was supported with infusions of phenylephrine and fluid. Upon discontinuation of isoflurane, the EEG showed disorganized delta activity, but there were no motor manifestations of clinical seizure. Urine fluoride excretion for the days after anesthesia was within normal limits. Following isoflurane administration the patient continued to demonstrate occasional facial twitching. Subsequently, she was discharged alive with partial return of cognitive function.

Case 3. A 2.5-yr-old girl with a prior history of petit mal seizures was admitted in generalized convulsive status epilepticus secondary to massive ingestion of organophosphate insecticide (carbophenothine [trithione]). She presented with salivation, lacrimation, and bradycardia with cyanosis, which progressed to cardiac arrest. Cardiopulmonary resuscitation was performed for 12 min. Successful resuscitation was followed several minutes later by the onset of focal motor seizure activity. Seizures subsequently progressed in the hospital to generalized tonic followed by tonic-clonic motor activity with generalized seizure activity on EEG. Seizures were treated with atropine, pralidoxime chloride, phenytoin, phenobarbital, diazepam, and pentobarbital (17.3 mg/kg over 3.5 h). All failed to control EEG seizure activity, although convulsive manifestations of seizures were abolished. Twenty-two hours after the onset of seizure activity, isoflurane administration was begun. Before isoflurane spike and wave bursts lasting 6-7 s were present with 1- to 2-second interburst suppression intervals. EEG seizures were attenuated initially at an end-tidal isoflurane concentration of 0.8%, which subsequently had to be increased to 1.8% to satisfactorily attenuate seizure activity (fig. 1). Isoflurane was administered for 36.5 h, during which MAP was 48-73 mmHg (preseizure MAP 57 mmHg). MAP was supported with infusions of phenylephrine and fluids. With discontinuation of isoflurane, a disorganized delta activity dominated the EEG, without clinical motor seizure. The patient had a cough reflex and some spontaneous respirations. However, 12 h later, spontaneous systemic hypertension occurred, coinciding with cessation of EEG activity. Shortly thereafter the patient was determined to be brain dead.

TABLE 1. Summary of Patients Receiving Isoflurane Anesthesia for Status Epilepticus

Patient No.	Age (yr)	Etiology SE	Duration SE	Duration Given (h)	MAP Pre-Iso (mmHg)	MAP Range (mmHg)	Blood Pressure Support	SE When Stopped	Outcome*
1	29	Idiopathic	32 d	1	76	75	Phenylephrine	Yes	Expired 12 d post-Iso secondary to SE
1	29	Idiopathic	40 d	5	90	70-77	Phenylephrine	Yes	
2	10	Idiopathic	27 d	48	92	61-80	Fluids Phenylephrine	No	Survived Partial return of cognitive and motor function Normal urine fluoride
3	2	Organophosphate Insecticide Ingestion	22 h	38	57	48-73	Fluids Phenylephrine	No	Expired 12 h post-Iso Abrupt onset EEG silence
4	6	Myoclonic s/p liver transplantation	1 d	1	75	47-75	Fluids Trendelenburg position	Yes	Survived Seizures gradually resolved over several weeks post-Iso Cognitive deficit
5	13	S/P AVM resection	40 d	4	77	65-67	Fluids Phenylephrine	Yes	Expired secondary to SE
5	13	S/P AVM resection	42 d	55	70	58-80	Fluids Phenylephrine	Yes	
6	30	Idiopathic	7 d	45	77	63-80	Fluids Dopamine	No	Expired secondary to multiorgan failure 7 wk post-Iso High (nontoxic) urine fluoride during and after Iso
7	64	S/P cerebral aneurysm clipping	5 d	47	70	62-101	Fluids Dopamine Epinephrine	Yes	Expired 2 d post-Iso secondary to SE
8	59	Bacterial meningitis	22 h	12	55	53-63	Fluids Dopamine	Yes	Expired 2 d post-Iso secondary to SE and sepsis
9	4	Idiopathic	7 d	8	84	49-68	Dopamine Dobutamine	Yes	Survived Partial return of cognitive and motor function

Data indicated were obtained from 11 separate administrations of isoflurane to nine patients with refractory status epilepticus. Data were obtained retrospectively in all patients except patients 2 and 3. Patients 1 and 2 were previously reported.^{9,10} AVM = arteriovenous malfor-

mation; Iso = isoflurane; MAP = mean arterial pressure (diastolic pressure + 1/3 pulse pressure); SE = status epilepticus; s/p = status post.

* Survival indicates alive on hospital discharge.

Case 4. A 6.5-yr-old boy, an inpatient with a preexisting myoclonic seizure disorder, developed myoclonic status epilepticus after liver transplantation. Liver transplantation had been performed because of hepatocellular necrosis, presumed due to sodium valproate. Seizure activity had been intermittent over 3 days and became increasingly refractory to iv medications, including phenobarbital, phenytoin, lorazepam, diazepam, pyridoxine, and thiopental. After 1 day of unsatisfactory control of myoclonic seizure activity, a trial of isoflurane anesthesia was begun. Before anesthesia EEG revealed spike and wave discharges at 1-s intervals over the left hemisphere with occasional involvement of the right frontal area. Amplitude was maximal bifrontally. The right hemisphere also revealed polymorphic and at times slow waves with frequencies superimposed in the 12-15 Hz range. With induction of anesthesia with isoflurane and 50% N₂O, increasing attenuation of activity occurred such that by the time inspired concentration of isoflurane reached 3%, 8-10-second burst suppression intervals were achieved. Subsequently, 1-min intervals between bursts

were achieved. Isoflurane administration was continued for 1 h, during which MAP decreased from 75 to 47 mmHg. Blood pressure was supported with fluid infusions and the Trendelenburg position. With discontinuation of isoflurane, the same EEG pattern with concomitant myoclonic activity returned. Subsequently, seizures resolved gradually over several weeks with treatment consisting of phenobarbital, clonazepam, carbamazepine, and phenytoin. It was never clear to this patient's physicians, however, whether his motor activity represented a primary motor disorder related to cyclosporine use or true convulsive status epilepticus (Crumrine P: personal communication). Nevertheless, the patient survived to be discharged from the hospital with a cognitive deficit.

Case 5. A 13-yr-old girl presented in convulsive status epilepticus. She had resection of a cerebral arteriovenous malformation 8 yr earlier. Seizures were treated (at various times) with phenytoin, carbamazepine, phenobarbital, paraldehyde, hypothermia, lidocaine, magnesium, diazepam, and lorazepam. Seizure control during this time varied from

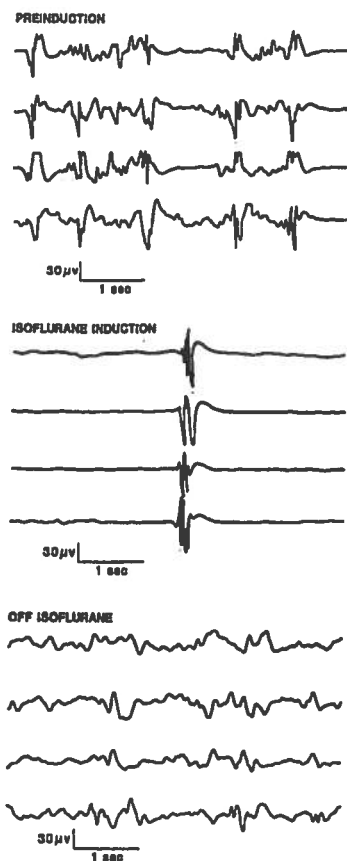


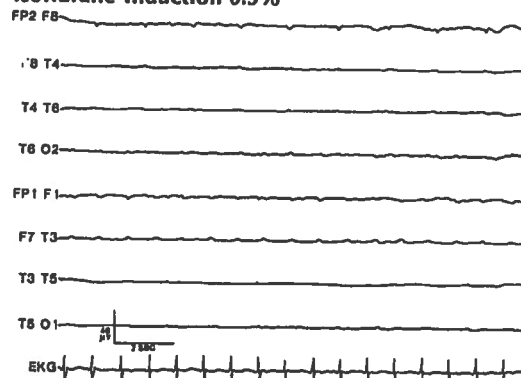
FIG. 1. Isoflurane was administered to a 2-yr-old girl with refractory status epilepticus secondary to ingestion of organophosphate insecticide (patient 3).

inadequate, with continued convulsive seizures, to good attenuation with periods of electrocerebral silence. Clinical manifestations of seizures also were variable, being occasionally electrical only and at other times convulsive. On the 40th hospital day during a bout of convulsive seizures, isoflurane was administered for 2 h. Inspired isoflurane concentrations of 0.7–1.3% were required to attenuate these seizures. MAP was maintained at 65–67 mmHg with iv phenylephrine and fluid infusions. Convulsive seizures recurred on discontinuation of isoflurane. On the 42nd hospital day, isoflurane was administered again. During the 56 h of anesthesia blood pressure was again maintained with iv infusions of phenylephrine and fluids; MAP ranged from 50 to 80 mmHg. Initially, end-tidal isoflurane concentration of 0.3–0.5% attenuated the seizures with no bursts for up to 5 min. Subsequently, as infusions of other anticonvulsant agents were discontinued, inspired isoflurane concentrations of 2.5–3.0% were required; ultimately, its concentration was maintained between 4% and 5% for approximately 10 h (fig. 2). During isoflurane administration five convulsive seizures lasting up to several minutes required additional increases in isoflurane concentration. Nevertheless, occasional motor seizure activity was still manifest as facial twitching, which corresponded to isolated spikes on EEG. With cessation of isoflurane, convulsive seizure activity returned. Shortly thereafter the patient was transferred to another hospital where she died of refractory status epilepticus.

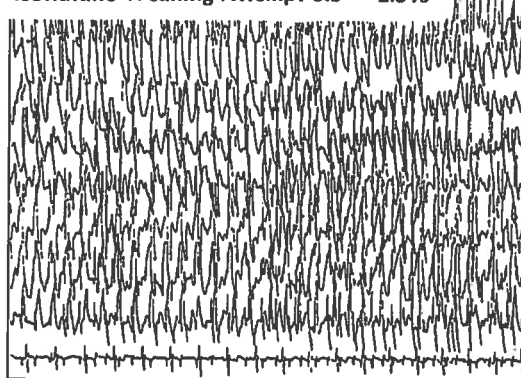
Case 6. A 30-yr-old woman presented with convulsive status epilepticus several days after a viral syndrome. She had a history of cerebral palsy and spastic quadriplegia (greater on the right side). She had intermittent convulsive tonic-clonic status epilepticus at another hospital for 1 month before admission. Her various treatments, including diazepam, phenytoin, paraldehyde, lidocaine, phenobarbital, and thio-

penthal, had controlled the seizure intermittently. Because of increasing difficulty in controlling status epilepticus by these means, isoflurane was administered on the 38th hospital day. At this time generalized EEG seizure bursts were present with interburst intervals up to 6 s and right upper extremity myoclonus. Isoflurane was continued for 45 h, during which MAP was maintained at 65–80 mmHg, with iv infusion of dopamine and fluids. Seizure activity was attenuated initially at an inspired isoflurane concentration of 0.5%, which subsequently had to

Isoflurane Induction 0.5%



Isoflurane Weaning Attempt 3.5 → 2.5%



Increase Isoflurane 4%

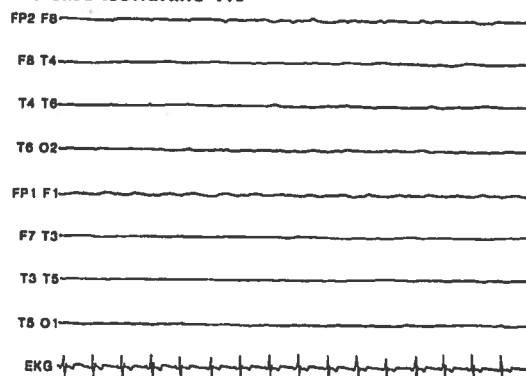


FIG. 2. A 13-yr-old girl received isoflurane for idiopathic refractory status epilepticus (patient 5). Increasing inspired concentrations of isoflurane were required. Depicted is the effect of decreasing the dose of isoflurane, which prompted the recurrence of pronounced electrographic and convulsive seizure activity. This activity resolved with an increase in isoflurane concentration. EEG was not recorded during isoflurane induction. For all three epochs sensitivity is 2 μ V/mm with a paper speed of 15 mm/s. (The same montage was used for the middle epoch.)

be increased to 1% to attenuate seizures for the subsequent 27 h of isoflurane administration. Isoflurane increased interburst intervals to 10–12 s and controlled motor activity in the right upper extremity. With cessation of isoflurane, convulsive seizure activity did not immediately recur, although occasional seizure spikes and intermittent convulsive seizures did eventually occur. The patient went on to develop multiorgan failure and died 7 weeks later without regaining consciousness. Urine fluoride concentrations on the first 4 days after isoflurane administration began were 187.5, 200, 108, and 34 $\mu\text{mol/l}$, respectively (normal, 10.5–57.9 $\mu\text{mol/l}$). Serum fluoride levels during isoflurane administration were 9.1 on day 1 and 7.0 on day 2 (normal 0.5–10.5 $\mu\text{mol/l}$). Urine output during isoflurane administration varied from 30 to 200 ml/h with a total 45-h intake and output of 8,144 and 3,261 ml, respectively.

Case 7. A 64-yr-old woman was admitted for elective clipping of a right middle cerebral artery aneurysm. On two prior occasions she had had subarachnoid hemorrhages, each with clipping of cerebral aneurysms. This clipping was uneventful intraoperatively, but shortly after the patient's arrival in the surgical intensive care unit, she developed generalized tonic-clonic seizures. Postoperative cranial computed tomogram showed a small frontal lobe hemorrhage remote from the operative site. For the first 5 postoperative days, convulsive seizures were controlled with phenytoin, diazepam, phenobarbital, paraldehyde, and an iv infusion of pentobarbital. However, EEG continued to show occasional seizure bursts, which responded to phenobarbital. On the fifth postoperative day, pentobarbital was discontinued and EEG evidence of seizures recurred. Isoflurane was started, and at inspired concentrations of 1.3–1.7% attenuated the seizures. Burst-suppression intervals were 4–8 s at the onset of isoflurane administration and subsequently increased to 4–68 s. MAP was maintained above 60 mmHg with iv infusions of dopamine and epinephrine. After 48 h isoflurane was discontinued and convulsive status epilepticus recurred. The patient died 2 days later of refractory status epilepticus.

Case 8. A 59-yr-old woman with a history of right ear pain and angina pectoris presented with convulsive seizures manifested by leftward turning of head, neck, and eyes with occasional generalization. These seizures responded to iv phenytoin. Subsequent evaluation resulted in a diagnosis of acute *Streptococcus pneumoniae* meningitis secondary to suppurative otitis media and mastoiditis. An emergent modified radical mastoidectomy was performed under thiopental, morphine, and isoflurane anesthesia. Within 30 min of the patient's arrival in the intensive care unit, partial and generalized convulsive seizures occurred. Phenytoin and phenobarbital failed to control the seizures. After 8 h of convulsive status epilepticus the patient was given 5 mg diazepam iv and was transported to the operating room for administration of inhaled isoflurane anesthesia. Seizure activity had subsided by the time isoflurane was started. Nevertheless, isoflurane was administered for 45 min, with a maximum end-tidal concentration of only 0.07% achieved. MAP, which started at 47 mmHg, did not change during this period, and no motor seizure activity was observed. However, convulsive status epilepticus resumed shortly after return to the intensive care unit and continued for 12 h despite therapy with phenytoin, phenobarbital, diazepam, and paraldehyde. Developing renal insufficiency was noted. A second course of isoflurane was then administered in the intensive care unit and was continued for 12 h. Seizures were suppressed initially at an inspired isoflurane concentration of 1%. This was increased to a maximum of 3.75% with a maximum end-tidal concentration of 2.1% needed to produce a burst-suppression pattern on EEG with 15–30-s isoelectric intervals. MAP was maintained at the pretreatment level of 55–63 mmHg throughout anesthetic administration, with central venous pressure increasing from 11 mmHg to a maximum of 20 mmHg. After 4 h of isoflurane administration and 600 ml of additional crystalloids, a dopamine infusion was used to support MAP and inspired isoflurane was increased from 2.5% to 3.74% (end-tidal 1.7% to 2.1%). With cessation of isoflurane administration, convulsive status epilepticus resumed and continued essentially un-

abated. The patient died 2 days later, secondary to systemic complications of refractory status epilepticus and systemic sepsis.

Case 9. A 4.5-yr-old boy with a 1-week history of febrile illness with sore throat and vomiting presented after a 2-day course at another hospital of intermittent idiopathic tonic-clonic seizures. Seizures had been unsuccessfully treated with phenobarbital, phenytoin, and rectal paraldehyde at the initial institution. He was subsequently transferred to the tertiary hospital where the seizures were treated with phenytoin, phenobarbital, and diazepam, also without success. On the fourth hospital day (2 days after transfer) a 1-week trial of pentobarbital was started and he was made hypothermic and was hyperventilated, requiring vasopressors for blood pressure support. With this treatment seizures stopped initially, with EEG becoming isoelectric. However, a burst-suppression pattern subsequently developed followed by recurrence of seizures, despite therapeutic anticonvulsant blood levels. After discontinuation of pentobarbital, on the 13th hospital day, isoflurane was administered for seizure control. Prior to the initiation of isoflurane the patient had either subtle (eye fluttering) or electrographic seizure activity every 5–20 min. Isoflurane was started at 1% administered, resulting initially in a burst-suppression pattern with an interburst interval of 6–10 s. This subsequently progressed to interburst intervals from 50–60 s to as long as 5 min. Isoflurane was continued for 8 h at a vaporizer concentration of 0.5–2.25%. During isoflurane administration MAP decreased from 80 to 57 mmHg where it remained for the entire isoflurane course. At the onset of isoflurane therapy, dopamine and dobutamine were infused at 7 and 2 $\mu\text{g} \cdot \text{kg}^{-1} \cdot \text{min}^{-1}$, respectively. They were not increased with isoflurane administration, and only maintenance crystalloid administration rate was used. There were eight instances of increased seizure pattern on EEG, usually after stimulation of the patient, which were treated with increased levels of administered isoflurane up to the maximum given of 2.25%. Isoflurane was titrated to produce interburst intervals of 15–20 s throughout its administration. Upon discontinuation of isoflurane, electrographic nonconvulsive seizure activity was noted 3, 6, 10, 18, 32, and 55 min later. After isoflurane administration the patient continued to demonstrate intermittent generalized convulsive seizure activity arising from various cortical regions. The patient subsequently was discharged 1 month later with a nonconvulsive epileptiform pattern on EEG with cognitive and motor deficits.

Six months later the patient was again admitted with convulsive status epilepticus. This time it was successfully treated using high-dose phenobarbital only with the patient surviving to be discharged from the hospital.

Discussion

Treatment protocols for convulsive status epilepticus indicate that when conventional means fail to control seizure activity an anesthesiologist should be called to give general anesthesia.^{2,3} Although there is no experimental or clinical evidence to support its use, halothane is the recommended agent.^{2,3} Unfortunately, halothane has the potential for organ toxicity and produces an isoelectric EEG only at doses associated with serious hemodynamic⁴ (and perhaps metabolic^{6,11}) consequences. Isoflurane has no known organ toxicity and produces EEG suppression at a hemodynamically acceptable dose.^{4,6–8} Yet, little is known about its use for refractory seizures. Thus, we reviewed these cases to assess the efficacy and safety of isoflurane given as an emergency measure to control life-threatening refractory status epilepticus in humans.

DEPTH OF ANESTHESIA

What constitutes control of seizures in cases such as these? One could argue that by producing a burst-suppression pattern with isoflurane, one has merely prolonged the interval between seizure spikes, thus attenuating rather than controlling the seizures. This issue suggests, therefore, that intensity of seizure activity (a subject that has not been studied) is important with respect to both amplitude and frequency of seizure spikes. More likely, however, the burst-suppression pattern we produced in these patients represents suppression of epileptic neural generators with emergence of the neural generators usually responsible for the burst-suppression pattern seen with deep isoflurane anesthesia in healthy people.

Unfortunately, no data are available to guide the clinician who is trying to decide how deeply to anesthetize a patient with status epilepticus. Thus, pending availability of such information, one is left to intuition based insofar as possible on available related data. Barbiturates in animals have been noted to produce maximal depression of cerebral metabolism when a burst-suppression interval of 30 s is achieved.¹² Thus, a burst-suppression interval of 15–30 s seems a reasonable goal in titrating isoflurane in such patients with refractory seizures.

Perhaps inducing a sustained period of EEG silence would be beneficial by suppressing an irritable focus, by analogy with suppression of reentrant ventricular arrhythmias.¹³ However, the adverse hemodynamic effects of isoflurane apparent in our patients and the lack of substantiating data suggest that the risks of such a maneuver will usually outweigh its possible benefits.

EFFECTS ON PATHOGENETIC PROCESSES

Whether isoflurane in our patients attenuated seizure activity or controlled an irritable seizure focus is an interesting question but is a moot point; in any case, the brain-damaging potential of seizure-induced hypermetabolism is most likely lessened with the burst-suppression pattern induced by isoflurane. That seizures resumed on discontinuation of isoflurane in eight of the 11 administrations suggests that at the doses we used, isoflurane cannot be expected to "control" seizures permanently or alter a seizure focus; most likely, it simply temporarily attenuates activity of epileptic neural generators. This is a reasonable goal, however, in a patient with life-threatening status epilepticus.

In three patients seizures did not resume. This could be expected to occur if isoflurane somehow improved pathogenetic processes. More likely, however, judging from the poor outcomes that nevertheless occurred, is that disease processes continued despite seizure control. It is possible that earlier use of isoflurane, within the 60-min "therapeutic window" proposed by Delgado-Escueta *et al.*,² could have prevented such poor neurologic outcomes. None of our patients received isoflurane this early, all having sustained seizures for prolonged periods.

Because of the rarity and sporadic occurrence of refractory convulsive status epilepticus, it would be exceedingly difficult to conduct a prospective clinical study of the various general anesthetics used as therapy to alter the consequences of convulsive status epilepticus. Preliminary results from animals suggest that isoflurane, other than effectively stopping seizures, does nothing to alter postictal brain damage ultimately sustained.¹⁴ Our series of cases supports these animal data because it provides no evidence that adverse neuropathologic processes were stopped (acknowledging that isoflurane use was started rather late in each case). Nevertheless, our cases suggest that isoflurane is usually effective in suppressing seizures and that, unlike all other anticonvulsant agents, it is readily titratable.

We clearly have not addressed the hypothesis that early use of isoflurane in status epilepticus can stop progression of seizure-induced neuropathology. To do this, anesthesiologists, on short notice, would have to give isoflurane for prolonged periods with therapy promptly initiated in the emergency room. Such an early role for isoflurane has certain attractions related to its titratability and reversibility. However, such a drastic change in current practice optimally should be supported by prospective studies, the difficulty of which for cases such as these is readily apparent.

ADVERSE SIDE EFFECTS

Hypotension. Most general anesthetics given to control seizures could be expected to produce a degree of hypotension. In our patients invasive monitoring was used and supplemental vasopressor and/or fluid infusions were required to maintain acceptable MAP. Nevertheless, the ready reversibility of the hemodynamic effects of isoflurane through either discontinuation or the use of pressors suggests that it may be a reasonable agent to consider if iv agents are hemodynamically unacceptable. We did have one patient, however, in whom epinephrine was required to support MAP and, in two patients multiorgan failure followed isoflurane use. Thus, the cardiovascular effects of isoflurane in this patient population should be considered with a cautious and individualized approach.

Fluoride release. Urine fluoride was measured in two patients who received isoflurane for a prolonged time. One patient showed no increase in urine fluoride after isoflurane. The other showed a clearly abnormal increase in urine fluoride concentration with a nontoxic⁶ increase in serum concentration without clinically apparent adverse effects. This case supports the observations of Davidkova *et al.*¹⁵ that fluoride ion can be released after isoflurane use, particularly prolonged use, and that (despite anticonvulsant use) nephrotoxic concentration of fluoride in the blood is difficult to achieve with isoflurane biodegradation.

Neurometabolic toxicity. One patient required 4–5% inspired isoflurane for several hours. A study in dogs has

shown neurometabolic toxicity with high concentrations of halothane,¹¹ whereas another study has suggested that high isoflurane concentrations are well tolerated metabolically.¹⁶ However, the potential for such concentrations of isoflurane to produce an adverse increase in brain lactate levels secondary to a dose-related increase in plasma glucose^{§§§} is unknown. High brain tissue levels of lactate have been correlated with brain damage in an animal seizure model.¹⁷ Furthermore, isoflurane reportedly can produce idiosyncratic seizures in humans¹⁸ and regional increases in cerebral metabolic rate in rats.¹⁹ This suggests the rare possibility that isoflurane could produce neuroexcitation, presumably due to excitatory neurotransmitter amino acids. Whether administration of high concentrations of isoflurane for seizures can produce or exacerbate an unacceptable increase in lactate or neurotoxic excitatory amino acids²⁰ is unknown.

Isoflurane appears to be an alternative, potent, titratable, reversible CNS depressant with substantial hemodynamic side effects that can be used to stop intractable seizures while reversible causes are elucidated. Our experience also suggests that it may be possible, by monitoring end-tidal isoflurane and degree of EEG burst suppression, to dynamically quantitate seizure threshold. However, pending more definitive results from animal studies or prospective clinical trials of earlier use of isoflurane, we cannot recommend isoflurane as the first-line anesthetic agent to control convulsive status epilepticus. Because of the extensive clinical and laboratory experience with iv agents, such as barbiturates²¹ and benzodiazepines,²² we suggest that isoflurane be used only when such iv agents at general anesthetic doses are ineffective or might be producing physical dependence²³ (i.e., withdrawal seizures). If unacceptable adverse hemodynamic side effects are limiting the use of iv anesthetics, isoflurane is a reasonable alternative because of its relative lack of negative inotropic effects⁵ and the reversibility of its effects.

The authors thank Allan Ropper, M.D., Richard Dasheiff, M.D., and Patricia Crumrine, M.D., for their comments during preparation of the manuscript; Tina Taylor and Charlotte Kratovil for their expert assistance in typing of the manuscript; Elizabeth Cohn for editorial assistance; and the critical care nurses in the various North American intensive care units for their invaluable expertise in caring for these most challenging patients.

§§§ Zapp MA, Kofke WA, Davis DW, Derr J: Ischemia-induced brain lactic acidosis exacerbated by isoflurane and increasing concentrations of volatile anesthetics (abstract). *Anesthesiol Rev* 14:14, 1987.

References

- Gastaut H, Rajer J, Lob H: Les états de mal Epileptiques. Paris, Masson, 1967
- Delgado-Escueta AV, Wasterlain C, Treiman DM, Porter RJ: Management of status epilepticus. *N Engl J Med* 306:1337-1340, 1982
- Delgado-Escueta AV, Treiman DM, Walsh GD: The treatable epilepsies. *N Engl J Med* 308:1508-1514, 1576-1584, 1983
- Stockard J, Bickford R: The neurophysiology of anesthesia, A Basis and Practice of Neuroanesthesia. Edited by Gordon E. New York, Excerpta Medica, 1975, pp 3-46
- Hickey RF, Eger EI II: Circulatory pharmacology of inhaled anesthetics, Anesthesia. Edited by Miller RD. New York, Churchill Livingstone, 1986, pp 646-666
- Baden JM, Rice SA: Metabolism and toxicity of inhaled anesthetics, Anesthesia. Edited by Miller RD. New York, Churchill Livingstone, 1986, pp 701-744
- Eger EI II, Stevens W, Cromwell T: The electroencephalogram in man anesthetized with Forane. *ANESTHESIOLOGY* 35:504-508, 1971
- Pauca AL, Dripps RD: Clinical experience with isoflurane (Forane). *Br J Anaesth* 45:697-703, 1973
- Kofke WA, Snider MT, Young RSK, Ramer JC: Prolonged low-flow isoflurane anesthesia for status epilepticus. *ANESTHESIOLOGY* 62:653-656, 1985
- Michenfelder JD, Theye RA: In vivo toxic effects of halothane on canine cerebral metabolic pathways. *Am J Physiol* 229:1050-1055, 1975
- Ropper AH, Kofke WA, Bromfield EB, Kennedy SK: Comparison of isoflurane, halothane, and nitrous oxide in status epilepticus. *Ann Neurol* 19:98-99, 1986
- Kassell NF, Hitchon PW, Gerk MK, Sokoll MD, Hill TR: Alterations in cerebral blood flow, oxygen metabolism, and electrical activity produced by high dose sodium thiopental. *Neurosurgery* 7:598-603, 1980
- Schmidt FO, Erlanger J: Directional differences in the conduction of an impulse through heart muscle and their possible relation to extrasystolic and fibrillary contractions. *Am J Physiol* 87:326, 1928
- Kofke WA, Towfighi J, O'Connell BK, Derr J, Hawkins RA: Neuropathologic effects of anesthetics used to stop status epilepticus in rats (abstract). *ANESTHESIOLOGY* 67:A390, 1987
- Davidkova T, Kiduchi H, Fujii K, Mudaia K, Sato N, Kawachi S, Morio M: Biotransformation of isoflurane: Urinary and serum fluoride ion and organic fluorine. *ANESTHESIOLOGY* 69:218-222, 1988
- Newberg LA, Milde JH, Michenfelder JD: The cerebral metabolic effects of isoflurane at and above concentrations that suppress cortical electrical activity. *ANESTHESIOLOGY* 59:23-28, 1983
- Ingvar M, Folbergrova J, Siesjö B: Metabolic alterations underlying the development of hypermetabolic necrosis in the substantia nigra in status epilepticus. *J Cereb Blood Flow Metab* 7:103-108, 1987
- Poulton TJ, Ellingson RJ: Seizure associated with induction of anesthesia with isoflurane. *ANESTHESIOLOGY* 61:471-476, 1984
- Ori C, Dam M, Pizzolato G, Battistin L, Giron G: Effects of isoflurane anesthesia on local cerebral glucose utilization in the rat. *ANESTHESIOLOGY* 65:152-156, 1986
- Olney JW: Excitatory transmitters and epilepsy related brain damage. *Int Rev Neurobiol* 27:337-362, 1985
- Lowenstein DH, Aminoff MJ, Simon RP: Barbiturate anesthesia in the treatment of status epilepticus: Clinical experience with 14 patients. *Neurology* 38:395-400, 1988
- Tassinari CA, Daniele O, Michelucci R, Bureau M, Dravet C, Roger J: Benzodiazepines: Efficacy in status epilepticus. *Adv Neurol* 34:465-476, 1983
- Fraser HF, Wikler A, Essig CF, Isbell H: Degree of physical dependence induced by secobarbital or pentobarbital. *JAMA* 166:126-129, 1958