

Inclusion Criteria:

- Patients >1 month old with suspected community-acquired skin and soft tissue infection

Exclusion Criteria:

- Non-infectious causes of swelling, erythema and pain
- Patients <1 mos
- Head and neck infections
- Suspect osteomyelitis
- Suspect septic arthritis
- Device related infections
- Surgical site infections
- Pyomyositis
- Necrotizing fasciitis

Consider Surgical Service Consults (in ED)

Orthopedic Surgery:

- Deep extremity infection (e.g. Tenosynovitis, Presumed necrotizing fasciitis)
- Deep puncture wound of hand/fingers/feet

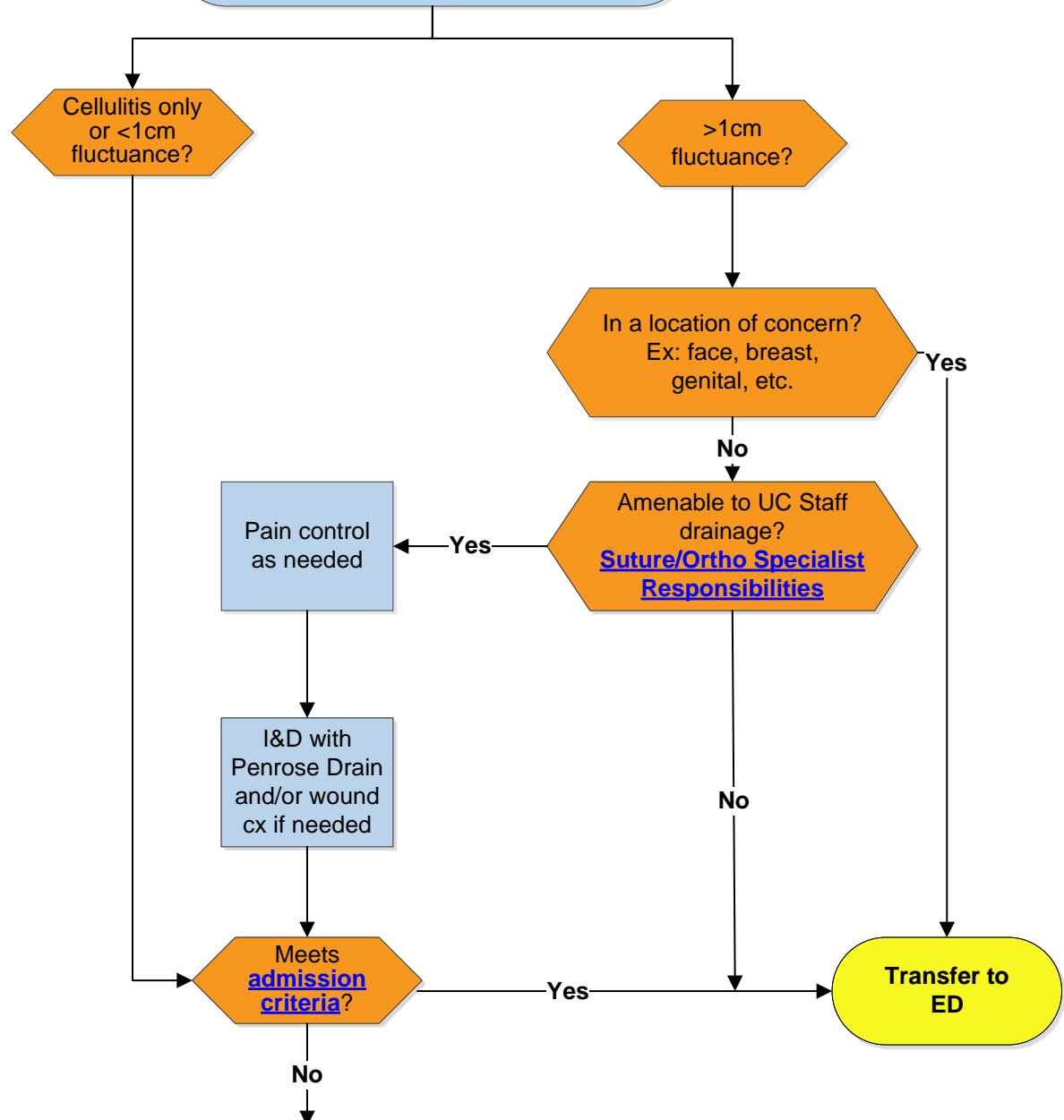
Pediatric Surgery:

- Breast abscess
- Perianal abscess (within 1cm of anal verge)
- Genital abscess
- Surgical Site Infections
- External neck abscess

ENT:

- Face or deep neck abscess

Initial UC Assessment of Suspected SSTI
Obtain History and Physical including exam of skin infection



- Discharge abscesses with PCP follow up in 7 days if drain has not fallen out; sooner if symptoms worsen.
- Discharge cellulitis with PCP follow up prn.
- Treat simple cellulitis with oral cephalexin x5 days. If recent history of MRSA, treat simple cellulitis with TMP-SMX or clindamycin for 5 days.
- Treat drained abscesses empirically with oral TMP-SMX or clindamycin for 5 days.
- Treat undrained <1cm abscess for 7 days with oral TMP-SMX or clindamycin.
- Prescribe definitive antibiotic therapy for MSSA/ Strep for outpatient treatment of simple cellulitis with known susceptibility.
- [Pilonidal discharge instructions and antibiotics](#)

[Differential Diagnoses](#)

[Treatment Recommendations](#)

[Treatments Not Recommended](#)

Diagnosis & Definition

The diagnosis of SSTI is usually based upon clinical manifestations of cellulitis or a soft-tissue abscess

- Cellulitis is an infection of the skin and underlying soft-tissue
- Soft-tissue abscess is a cavity filled with pus

Treatment of pediatric skin and soft-tissue infections is complex due to concern for antibiotic-resistant organisms. The leading cause of purulent infections is *S. aureus*. The leading cause of cellulitis is group A *Streptococcus* and other hemolytic streptococci, but may also be due to *Staph. aureus*.

Typical Presentation:

- Cellulitis: Manifests as areas of skin erythema, edema, pain and warmth
- Soft-tissue abscess: Manifests as a painful, fluctuant, erythematous nodule, with or without surrounding cellulitis

[Initial Assessment
Algorithm](#)

Pathway Objective

To improve the quality and safety of care for uncomplicated community acquired soft tissue infections/abscesses in children older than 30 days of life, specifically:

- Increase the use of bacterial cultures that will allow for targeted antimicrobial therapy
- Decrease unnecessary laboratory testing
- Reduce the use of systemic antibiotics for children with simple abscesses who meet low risk criteria
- Reduce the use of inappropriate antibiotics for cellulitis and abscess
- Decrease unnecessary hospital admissions

[Initial Assessment
Algorithm](#)

Differential Diagnoses

Findings suggestive of another diagnosis include:

- **Erythema migrans** – Erythema migrans is an early manifestation of Lyme disease; it consists of a region of erythema surrounding the site of a tick bite, infrequently with central clearing . The diagnosis is based on clinical findings. A similar lesion may occur in patients with Southern tick–associated rash illness.
- **Herpes zoster** – The rash of herpes zoster begins as erythematous papules that evolve into grouped vesicles. The rash is generally limited to one dermatome but can affect two or three neighboring dermatomes. The diagnosis is established by polymerase chain reaction of vesicular fluid.
- **Septic arthritis** – Cellulitis may overlie a septic joint. Clinical manifestations include joint pain, swelling, warmth, and limited range of motion. The diagnosis of septic arthritis is established based on synovial fluid examination/culture and PCR.
- **Osteomyelitis** – Osteomyelitis may underlie an area of cellulitis. It is prudent to pursue MRI imaging for assessment of bone involvement in the setting of point tenderness and/or limitation of movement in the affected area.
- **Contact dermatitis** – Contact dermatitis may be distinguished from cellulitis in that the contact dermatitis lesions are pruritic. Clinical features include erythema, edema, vesicles, bullae, and oozing. The reaction is generally limited to the site of contact and is associated with burning, stinging; it is not or only mildly painful.
- **Insect bite** – An insect bite triggers an inflammatory reaction at the site of the punctured skin, which appears within minutes and consists of pruritic local erythema and edema. In some cases, a local reaction is followed by a delayed skin reaction consisting of local swelling, itching, and erythema. It is not painful.
- **Vaccination site reaction** – A local reaction to vaccination manifests with erythema, swelling, and tenderness at the injection site; these are typically self-limited.

[Initial Assessment
Algorithm](#)

Admission Criteria

- Systemic signs of toxicity/bacteremia/sepsis
- Rapid progression of erythema
- Progression of clinical findings following an I&D and 48hrs of oral antibiotic therapy
- All <1mo
- Hospital-acquired and device-associated infections
- Presumed necrotizing fasciitis
- Pre/post-septal cellulitis
- Immunodeficiency
- Pressure ulcers
- Significant abscess due to animal/human bites
- Significant abscess associated with foreign body
- Inability to tolerate oral antibiotic therapy
- **Size alone should not determine need for admission, nor should fever alone**

[Initial Assessment
Algorithm](#)

Admission Matrix

- Admit patients to the Infectious Disease service if possible.
- If admission to the Infectious Disease Service is not possible, admit to Hospital Pediatrics.

[Initial Assessment
Algorithm](#)

Testing, Assessment & Monitoring

Testing

- Obtain wound cultures when possible.
Quality of evidence: Moderate, Recommendation: Strong

Assessment & Monitoring

- An Ultrasound is recommended if there is uncertainty in the physical exam of an abscess, or it is in a concerning location, such as the umbilicus, over a joint, peri-anal, or there is uncertainty in the depth of the infection
Quality of evidence: Moderate, Recommendation: Strong

[Initial Assessment
Algorithm](#)

Treatment Recommendations

Recommended Treatments

- With pain control, incise and drain any abscess > 1 cm and place a straight Penrose drain (if needed) into the abscess cavity for drainage and suture into place with Fast-absorbing suture
- Prescribe oral TMP-SMX (8-10 mg/kg/day bid) or clindamycin (30mg/kg/day tid) for outpatient treatment of abscesses. (*Quality of evidence: High, Recommendation: Strong*)
- Prescribe cephalexin (50mg/kg/day divided TID) for outpatient treatment of simple cellulitis. If recent history of MRSA, treat simple cellulitis with oral TMP-SMX (8-10 mg/kg/day bid) or clindamycin (30mg/kg/day tid).
- Treat simple cellulitis or an abscess that is fully drained for 5 days and an undrained abscess for a minimum of 7 days with appropriate follow up. (*Quality of evidence: Moderate, Recommendation: Strong*)
- PCP follow up is recommended in all patients and especially if symptoms worsen, persist or the Penrose drain hasn't fallen out after 7 days.

[Initial Assessment
Algorithm](#)

Treatment Not Recommended

- Do NOT obtain routine blood testing (CBC, CRP, blood culture) for most children with cellulitis or abscess.
Quality of evidence: High, Recommendation: Strong
- No incision and drainage is needed for abscesses <1 cm on physical examination; these patients may be discharged home on antibiotics alone based on risk factors.
Quality of evidence: Low, Recommendation: Strong
- Do not unroof or needle aspirate any abscess greater than 1cm, instead perform an I&D.
Quality of evidence: High, Recommendation: Strong

[Initial Assessment
Algorithm](#)

Deterioration & Escalation of Care

Identification of Deterioration

- It should not be considered failure of oral therapy if there is a progression of clinical findings after oral antibiotic therapy if there is an abscess, and an I&D has not been performed
- If after an I&D, which is followed by 48hrs of oral antibiotic therapy and there is a progression of clinical findings, it should be considered a failure of outpatient management
- If there is progression of clinical findings after 48hrs and an ultrasound shows no abscess, it should be considered a failure of outpatient management

Escalation of Care Protocol

- If there is a failure of outpatient management, the patient will require admission

[Initial Assessment
Algorithm](#)

Discharge Criteria & Planning

- Discharge if patient can tolerate oral antibiotics and if an abscess was present, it has been adequately drained if needed.
- Treat simple cellulitis or drained abscesses empirically with oral TMP-SMX or clindamycin for 5 days.
- Treat undrained <1cm abscess for 7 days with oral TMP-SMX or clindamycin.
- Prescribe definitive antibiotic therapy for MSSA/Strep for outpatient treatment of simple cellulitis with known susceptibility.
- PCP follow up is recommended in all patients and especially if symptoms worsen, persist, or the drain, if placed, hasn't fallen out after 7 days.

[Initial Assessment
Algorithm](#)

Patient Education

- Helping Hands [MRSA decolonization](#)
- Helping Hands [MRSA Infection in the Community \(Methicillin Resistant Staphylococcus Aureus\)](#)
- Helping Hands [Pilonidal Disease](#)

[Initial Assessment
Algorithm](#)

Provider Education

1. Management of Cutaneous Abscess:

- a. Cleanse site with antiseptic solution.
- b. First anesthetize surrounding non-infected skin and subcutaneous tissue with topical anesthetic, or local anesthetic by local infiltration or regional block.
- c. The roof of the abscess should be anesthetized by intradermal injection along the course of the proposed incision.
- d. Culture and gram stain may be indicated for cutaneous abscesses because of increasing risk of antibiotic resistant micro-organisms.
- e. A roof incision is made that is sufficient in length to facilitate drainage and packing if needed.
- f. After the incision, gently probe the abscess with either a pair of hemostats or if possible your finger.
- g. Once the entire abscess cavity has been explored and loculations opened, irrigate with normal saline. Spread open abscess with blunt hemostat or fingers. Irrigation is considered adequate when the saline is free of pus and appears blood-tinged. Consider use of Yankauer suction tip on low suction to facilitate removal of pus and irrigant solution.
- h. If necessary, gently insert a penrose drain into the abscess, and suture in place with fast absorbing gut sutures. The purpose of the penrose drain is to promote continuous drainage from the abscess cavity.
- i. Occlusive dressings should not be applied routinely, as they may cause retention of infectious material in the wound. A partially occlusive dressing, which still promotes wound drainage, may be considered in areas which are likely to become contaminated (such as near the anus).

2. Analgesia

When examining a suspected abscess, palpation does not always reveal fluctuance. I & D's are extremely painful, so local analgesia is paramount.

At times, local analgesia may not be enough and transfer to the Emergency Department for procedural sedation and analgesia may be needed.

[Initial Assessment
Algorithm](#)

Suture/Orthopedic Specialist (Suture Tech) I & D Procedural Responsibilities

1. Suture technicians may incise and drain subcutaneous abscesses.
2. Suture technicians should not incise and drain abscesses that are:
 - a. Associated with significant systemic illness.
 - b. The following anatomical locations*:
 - i. Face
 - ii. Neck
 - iii. Perianal: i.e. extension to the anus
 - iv. Genital (labia, penis, scrotum, breast)
 - c. Abscesses that have more complex anatomical concerns such as bone, joint, cartilage, lymph node, deep fascia or muscle layer involvement.
 - d. The incision will cause a significant cosmetic concern to the patient or family.

*Abscess drainage may be performed by the ST/OT or LPN/ST if there is no significant risk of injury to nerves or other underlying structures, or minimal risk of poor cosmetic outcome, AND the ED/Urgent Care Attending and ST/OT both are competent to perform the procedure. This can be determined by the ED/UC Attending.

[Initial Assessment
Algorithm](#)

Risk Awareness & Zero Hero

Decrease hospital acquired harm by decreasing surgical complication and increasing healthcare value

[Initial Assessment
Algorithm](#)

Pathway Team & Process

Pathway Development Team

Leaders:

Emergency Medicine:

Betsy Schmerler, MD

Urgent Care:

Luciana Berg, MD

Infectious Diseases:

Guliz Erdem, MD

Members:

Emergency Services:

Michael Dunn, MD

Pediatric Surgery:

Gail Besner, MD

Brian Kenney, MD, MPH

Dana Noffsinger

Clinical Pathways Program:

Medical Director – Emergency Medicine:

Berkeley Bennett, MD, MS

Medical Director – Clinical Informatics & Emergency Medicine:

Laura Rust, MD, MPH

Physician Informatics:

Juan Chaparro, MD

Business & Development Manager:

Rekha Voruganti, MBOE, LSSBB

Program Coordinators:

Tahje Brown, MBA

Tara Dinh, BS

Clinical Pathway Approved:

Medical Director – Associate Chief Quality Officer, Center for Clinical Excellence:

Ryan Bode, MD, MBOE

Origination Date: October, 2024

Next Revision Date: October, 2027

Clinical Pathway Development

This clinical pathway was developed using the process described in the NCH Clinical Pathway Development Manual Version 6, 2022. Clinical Pathways at Nationwide Children's Hospital (NCH) are standards which provide general guidance to clinicians. Patient choice, clinician judgment, and other relevant factors in diagnosing and treating patients remain central to the selection of diagnostic tests and therapy. The ordering provider assumes all risks associated with care decisions. NCH assumes no responsibility for any adverse consequences, errors, or omissions that may arise from the use or reliance on these guidelines. NCH's clinical pathways are reviewed periodically for consistency with new evidence; however, new developments may not be represented, and NCH makes no guarantees, representations, or warranties with respect to the information provided in this clinical pathway.

Copyright © 2023. Nationwide Children's Hospital. All rights reserved. No part of this document may be reproduced, displayed, modified, or distributed in any form without the express written permission of Nationwide Children's Hospital.

**For more information about our pathways and program please contact:
ClinicalPathways@NationwideChildrens.org**

[Initial Assessment
Algorithm](#)

References

- Kilburn SA, Featherstone P, Higgins B, Brindle R. Interventions for cellulitis and erysipelas. *Cochrane Database Syst Rev*. 2010;2010(6):CD004299. Published 2010 Jun 16. doi:10.1002/14651858.CD004299.pub2
- Liu C, Bayer A, Cosgrove SE, et al. Clinical practice guidelines by the infectious diseases society of america for the treatment of methicillin-resistant Staphylococcus aureus infections in adults and children [published correction appears in Clin Infect Dis. 2011 Aug 1;53(3):319]. *Clin Infect Dis*. 2011;52(3):e18-e55. doi:10.1093/cid/ciq146
- Robinson JL, Salvadori MI. Management of community-associated methicillin-resistant Staphylococcus aureus skin abscesses in children. *Paediatr Child Health*. 2011;16(2):115-118. doi:10.1093/pch/16.2.115
- Elliott DJ, Zaoutis TE, Troxel AB, Loh A, Keren R. Empiric antimicrobial therapy for pediatric skin and soft-tissue infections in the era of methicillin-resistant Staphylococcus aureus. *Pediatrics*. 2009;123(6):e959-e966. doi:10.1542/peds.2008-2428
- Duong M, Markwell S, Peter J, Barenkamp S. Randomized, controlled trial of antibiotics in the management of community-acquired skin abscesses in the pediatric patient. *Ann Emerg Med*. 2010;55(5):401-407. doi:10.1016/j.annemergmed.2009.03.014
- Williams DJ, Cooper WO, Kaltenbach LA, et al. Comparative effectiveness of antibiotic treatment strategies for pediatric skin and soft-tissue infections. *Pediatrics*. 2011;128(3):e479-e487. doi:10.1542/peds.2010-3681
- Chen AE, Carroll KC, Diener-West M, et al. Randomized controlled trial of cephalexin versus clindamycin for uncomplicated pediatric skin infections. *Pediatrics*. 2011;127(3):e573-e580. doi:10.1542/peds.2010-2053
- Liu C, Bayer A, Cosgrove SE, et al. Clinical practice guidelines by the infectious diseases society of america for the treatment of methicillin-resistant Staphylococcus aureus infections in adults and children [published correction appears in Clin Infect Dis. 2011 Aug 1;53(3):319]. *Clin Infect Dis*. 2011;52(3):e18-e55. doi:10.1093/cid/ciq146
- Stevens DL, Bisno AL, Chambers HF, et al. Practice guidelines for the diagnosis and management of skin and soft tissue infections: 2014 update by the infectious diseases society of America. *Clin Infect Dis*. 2014;59(2):147-159. doi:10.1093/cid/ciu296
- Moran GJ, Krishnadasan A, Mower WR, et al. Effect of Cephalexin Plus Trimethoprim-Sulfamethoxazole vs Cephalexin Alone on Clinical Cure of Uncomplicated Cellulitis: A Randomized Clinical Trial. *JAMA*. 2017;317(20):2088-2096. doi:10.1001/jama.2017.5653
- Pallin DJ, Binder WD, Allen MB, et al. Clinical trial: comparative effectiveness of cephalexin plus trimethoprim-sulfamethoxazole versus cephalexin alone for treatment of uncomplicated cellulitis: a randomized controlled trial. *Clin Infect Dis*. 2013;56(12):1754-1762. doi:10.1093/cid/cit122
- Schmitz GR, Bruner D, Pitotti R, et al. Randomized controlled trial of trimethoprim-sulfamethoxazole for uncomplicated skin abscesses in patients at risk for community-associated methicillin-resistant Staphylococcus aureus infection [published correction appears in Ann Emerg Med. 2010 Nov;56(5):588]. *Ann Emerg Med*. 2010;56(3):283-287. doi:10.1016/j.annemergmed.2010.03.002
- Miller LG, Daum RS, Creech CB, et al. Clindamycin versus trimethoprim-sulfamethoxazole for uncomplicated skin infections. *N Engl J Med*. 2015;372(12):1093-1103. doi:10.1056/NEJMoa1403789
- Vermandere M, Aertgeerts B, Agoritsas T, et al. Antibiotics after incision and drainage for uncomplicated skin abscesses: a clinical practice guideline. *BMJ*. 2018;360:k243. Published 2018 Feb 6. doi:10.1136/bmj.k243
- Marin JR, Dean AJ, Bilker WB, Panebianco NL, Brown NJ, Alpern ER. Emergency ultrasound-assisted examination of skin and soft tissue infections in the pediatric emergency department. *Acad Emerg Med*. 2013;20(6):545-553. doi:10.1111/acem.12148
- Holmes L, Ma C, Qiao H, et al. Trimethoprim-Sulfamethoxazole Therapy Reduces Failure and Recurrence in Methicillin-Resistant Staphylococcus aureus Skin Abscesses after Surgical Drainage. *J Pediatr*. 2016;169:128-34.e1. doi:10.1016/j.jpeds.2015.10.044
- Hester G; Hersh AL; Mundorff M; Korgenski K; Wilkes J; Stoddard G; Byington CL; Srivastava R. Outcomes After Skin and Soft Tissue Infection in Infants 90 Days Old or Younger. *Hospital Pediatrics*. 5(11):580-5, 2015 Nov.
- Trenchs V, Hernandez-Bou S, Bianchi C, Arnan M, Gene A, Luaces C. Blood Cultures Are Not Useful in the Evaluation of Children with Uncomplicated Superficial Skin and Soft Tissue Infections. *Pediatr Infect Dis J*. 2015;34(9):924-927. doi:10.1097/INF.0000000000000768
- Cadena J, Nair S, Henao-Martinez AF, Jorgensen JH, Patterson JE, Sreeramaju PV. Dose of trimethoprim-sulfamethoxazole to treat skin and skin structure infections caused by methicillin-resistant Staphylococcus aureus. *Antimicrob Agents Chemother*. 2011;55(12):5430-5432. doi:10.1128/AAC.00706-11
- Gottlieb M, Peksa GD. Comparison of the loop technique with incision and drainage for soft tissue abscesses: A systematic review and meta-analysis. *Am J Emerg Med*. 2018;36(1):128-133. doi:10.1016/j.ajem.2017.09.007
- Alder AC, Thornton J, McHard K, Buckins L, Barber R, Skinner MA. A comparison of traditional incision and drainage versus catheter drainage of soft tissue abscesses in children. *J Pediatr Surg*. 2011;46(10):1942-1947. doi:10.1016/j.jpedsurg.2011.05.025
- Mahida JB, Sulkowski JP, Kurtovic KJ, et al. Using quality improvement methods to change surgical practice: a case example of pediatric soft-tissue abscesses. *Qual Manag Health Care*. 2015;24(2):84-90. doi:10.1097/QMH.0000000000000054
- Singer AJ, Richman PB, Kowalska A, Thode HC Jr. Comparison of patient and practitioner assessments of pain from commonly performed emergency department procedures. *Ann Emerg Med*. 1999;33(6):652-658.
- Gottlieb M, Schmitz G, Grock A, Mason J. What to Do After You Cut: Recommendations for Abscess Management in the Emergency Setting. *Ann Emerg Med*. 2018;71(1):31-33. doi:10.1016/j.annemergmed.2017.11.006
- McNamara WF, Hartin CW Jr, Escobar MA, Yamout SZ, Lau ST, Lee YH. An alternative to open incision and drainage for community-acquired soft tissue abscesses in children. *J Pediatr Surg*. 2011;46(3):502-506. doi:10.1016/j.jpedsurg.2010.08.019
- Gaspari RJ, Resop D, Mendoza M, Kang T, Blehar D. A randomized controlled trial of incision and drainage versus ultrasonographically guided needle aspiration for skin abscesses and the effect of methicillin-resistant Staphylococcus aureus. *Ann Emerg Med*. 2011;57(5):483-91.e1. doi:10.1016/j.annemergmed.2010.11.021
- Daum RS, Miller LG, Immergluck L, et al. A Placebo-Controlled Trial of Antibiotics for Smaller Skin Abscesses. *N Engl J Med*. 2017;376(26):2545-2555. doi:10.1056/NEJMoa1607033
- Fisher RG, Chain RL, Hair PS, Cunnion KM. Hypochlorite killing of community-associated methicillin-resistant Staphylococcus aureus. *Pediatr Infect Dis J*. 2008;27(10):934-935. doi:10.1097/INF.0b013e318175d871

Pathway Team Publication:

Dunn M, Savoie K, Erdem G, et al. Quality improvement methodology can reduce hospitalisation for abscess management. *Emerg Med J*. Published online January 11, 2022. doi:10.1136/emered-2021-211466

[Initial Assessment](#)
[Algorithm](#)

Pilonidal Abscess

Antibiotics:

- **First time pilonidal abscess:** Amoxicillin/clavulanate for 5 days
- **Recurrent pilonidal abscess:** Amoxicillin/clavulanate for 5 days unless wound culture is positive for MRSA (let sensitivities guide antibiotic choice if MRSA positive).

Discharge Information:

- Use Pilonidal Abscess discharge instructions
- Refer to Pilonidal Clinic for follow up; suggest family ask for first available appointment
Located in the Surgery and Burn Clinic
OCC 6D
555 S 18th St
614-722-3900
- Provide Helping Hand on [Pilonidal Disease](#)

[Initial Assessment
Algorithm](#)