The Adolescent and Adult Congenital Heart Disease Program

The Heart Center at Nationwide Children's Hospital & The Ohio State University

Congenitally Corrected Transposition of the Great Vessels (l-TGA)

Congenitally corrected transposition of the great vessels (CCTGA; l-TGA) is an uncommon congenital heart abnormality, occurring in 0.5% of the population. In CCTGA, the receiving chambers (atria) are connected to their opposite pumping chambers (ventricles) because the ventricles are switched (inverted) from their normal anatomic positions. The aorta carries oxygen rich blood (red blood) to the body, whereas the pulmonary artery carries oxygen poor blood (blue blood). In CCTGA, the normally situated aorta comes off of the (inverted) right ventricle and the normally situated pulmonary artery comes off of the (inverted) left ventricle. The blue blood from the body flows through the mitral valve to the left ventricle and is pumped out to the lungs to get oxygen. The oxygen-rich blood from the lungs (red blood) flows through the tricuspid valve to the right ventricle, and is pumped to the body. The right heart structures-tricuspid valve and right ventricle normally function at low pressure.

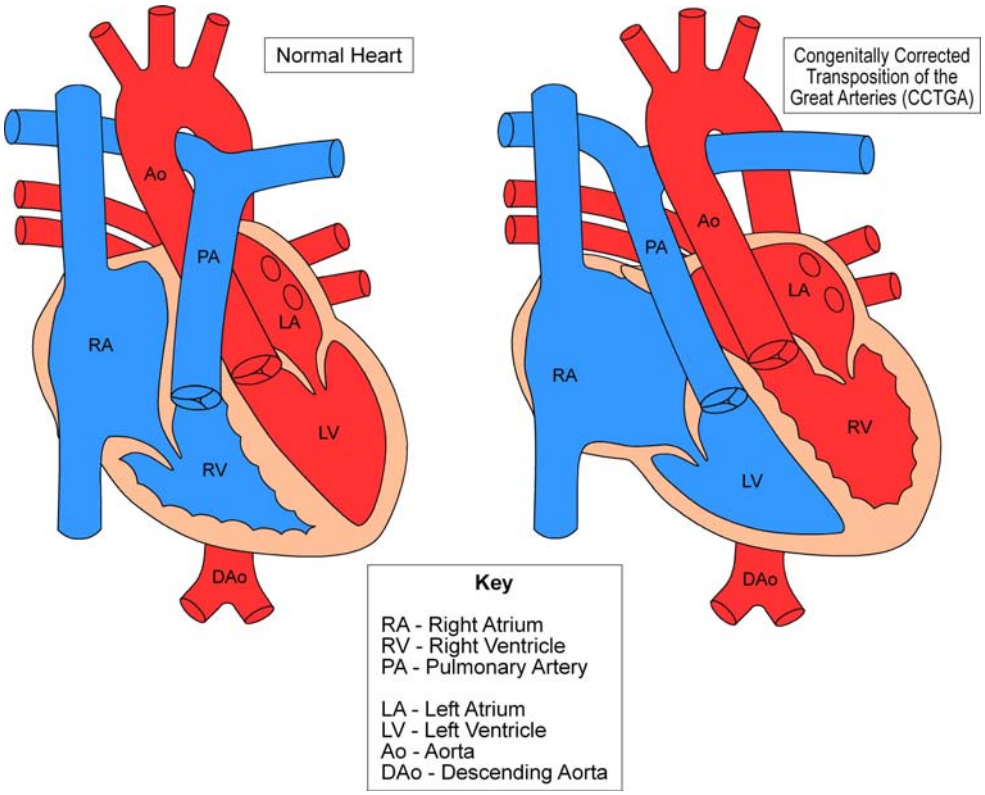

Left: Normal heart; normal atrial to ventricular and ventricular to arterial connections. Right: Congenitally corrected transposition of the great arteries. Blue blood from the body returns to the right atrium (RA), enters the ("inverted") left ventricle (LV) and is pumped through the pulmonary artery to the lungs. Oxygenated (red) blood from the lungs returns to the left atrium (LA), enters the ("inverted") right ventricle (RV) and is pumped through the aorta to the body.

The normally oriented lower part of the heart (ventricular apex) sits in the left chest. In approximately 20% of patients with CCTGA, the ventricular apex sits in the right chest, a condition called dextrocardia. Dextrocardia is usually evident by abnormal cardiac examination, atypical electrocardiographic (EKG) and chest x-ray findings. Situs inversus occurs in 5% of patients with CCTGA. In this condition, the major visceral organs are mirrored from their normal positions. Most patients will do extremely well for many years but as they approach late teenage years and into their 20s many problems are possible.

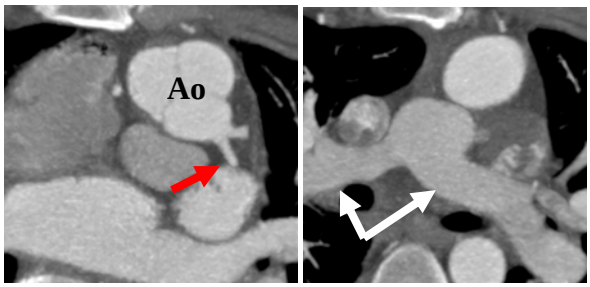

Cardiac CT images demonstrate the unusual relationship between the great arteries in CCTGA. The aorta (Ao) lies closer to the chest wall (top of image) and gives rise to the coronary arteries (red arrow) that supplies oxygen rich blood to the heart muscle. The pulmonary arteries (white arrows) lie behind the aorta, further from the chest wall and direct blood to the lungs, which are rightward and toward the patient's back (bottom of image).

Associated structural cardiac disorders include:

Pulmonary stenosis occurs in approximately 30-50% of CCTGA patients. There is muscular or valvular narrowing in the left ventricular outflow tract that results in diminished blood flow to the lungs and can result in bluish discoloration of the skins, tongue, lips and nail beds (cyanosis).

Ventricular septal defect (VSD), is an abnormal communication (hole) between the ventricles and occurs in 60-80% of patients with CCTGA.

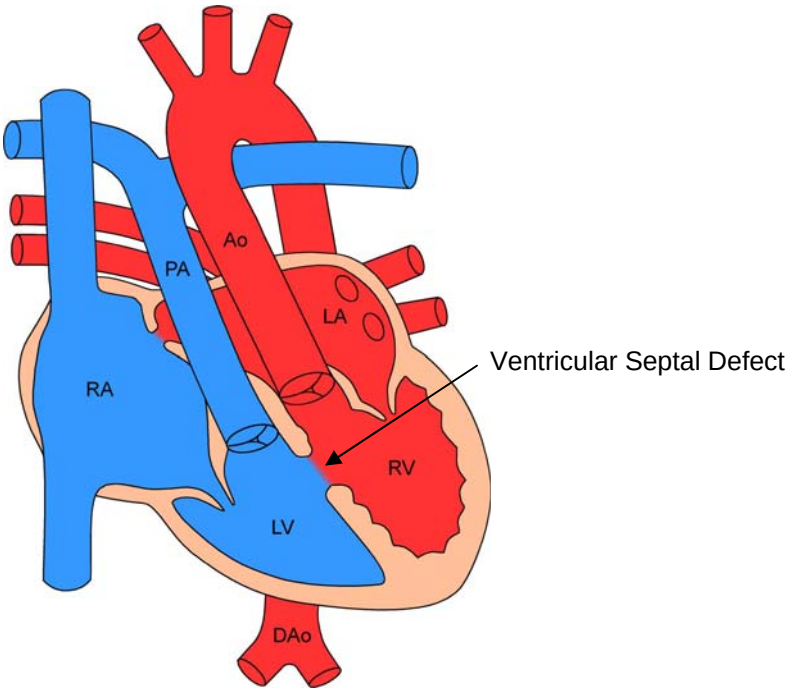

Tricuspid Valvular Abnormalities

In CCTGA, the right ventricle is the "systemic ventricle", which pumps blood to the body and must function at the body's blood pressure which is approximately four to five times higher than the pressure in the lungs. Blood flows through the tricuspid valve into the right ventricle. The tricuspid valve is exposed to a blood pressure that is also much higher. The tricuspid valve can be abnormally displaced in the lower right ventricular chamber; this condition is Ebstein anomaly. With aging patients with CCTGA can develop progressive leakiness (tricuspid regurgitation).

Cardiac Rhythms Disturbances (Arrhythmias)

CCTGA can be associated with abnormalities in the heart's electrical wiring (the conduction system). With advancing age some patients have a significantly increased risk of developing atrioventricular (AV) block; the treatment for advanced AV block is to have a pacemaker implanted. Pacemakers stimulate the heart, allowing it to beat fast enough. Symptoms of advanced AV block include lightheadedness, fainting and profound fatigue.

In patients with CCTGA, early heart beats (palpitations) and fast heart rhythms (racing or rapid and chaotic heart rhythm) can arise from either the upper (atrial) or lower (ventricular) chambers. Abnormalities in the specialized electrical tissues in the heart (AV node) are common in CCTGA patients, and can result in excessive slowing in the heart rate. Arrhythmias may require additional study of the heart's electrical wiring. Therapies needed to correct the heart rhythm can include medications, cardioversion/ablation, pacemaker and/or internal cardioverter defibrillator (ICD) implantation to restore normal heart rate and rhythm.

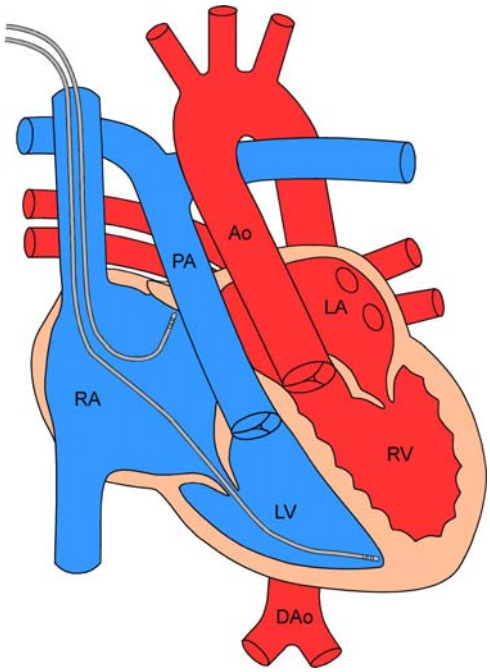

<u>Pacemaker Implantation in CCTGA</u> Pacing wires enter the right atrium through the large upper vein (superior vena cava), pass through the mitral valve, and the pacemaker lead (tip) is situated to stimulate the left ventricle.

Heart Failure Symptoms

Although the heart has normal physiologic blood flow, anatomic abnormalities still exist. The right ventricle, which usually pumps blood to the low blood pressure lungs now pumps blood to the body (high pressure). The right ventricle handles the pressure load fairly well for many years but eventually begins to wear down, becomes dilated and unfortunately the right ventricle will weaken. This weakening will be felt by patients as signs of heart failure; shortness of breath, fatigue, chest pain, decreased exercise ability. Treatments with medicines are almost always helpful and can restore some of the heart function and improve symptoms. If the function of the right ventricle continues to deteriorate despite medical treatment, heart transplant would be an option.

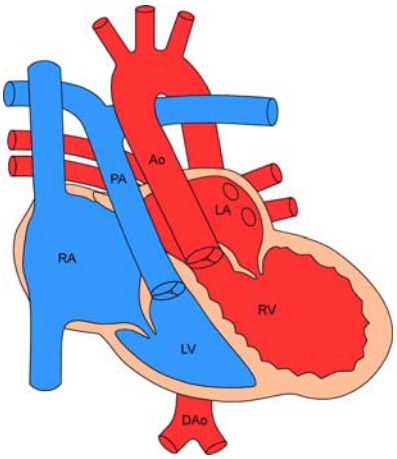

Severe right ventricular enlargement

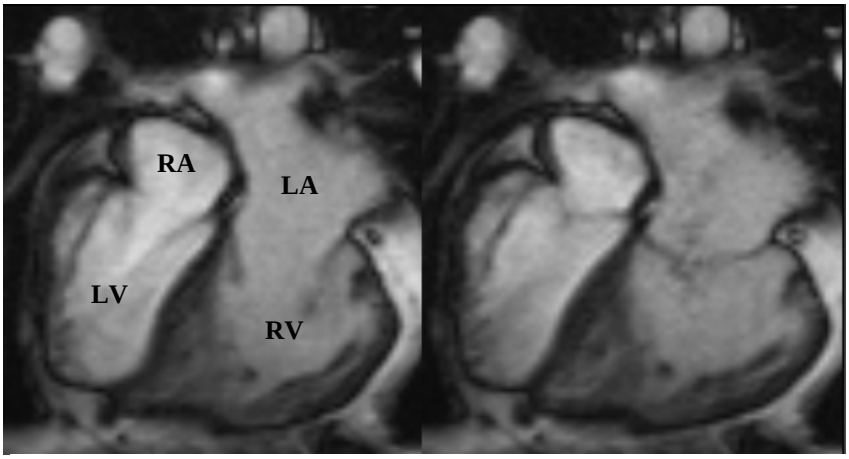

Cardiac MRI illustrates anatomy in a 52 year old woman with CCTGA. Left panel shows the heart during the resting phase (diastole); and the right panel shows the heart during the active phase (systole). LA=Left Atrium; RV=Right Ventricle; RA=Right Atrium; LV=Left Ventricle

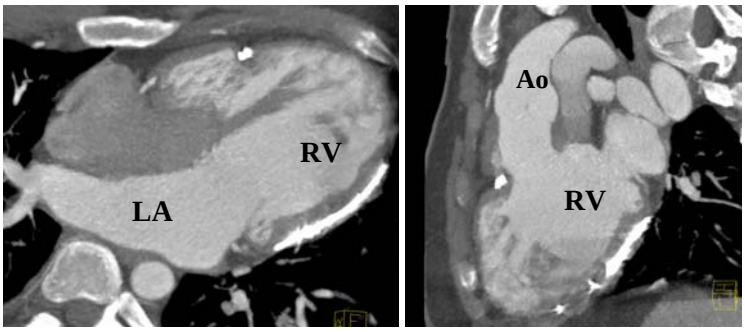

Cardiac CT is performed in patients who are unable to safely undergo cardiac MRI. Like MRI, CT also demonstrates anatomy of CCTGA. The image on the left is similar to the cardiac MR images above. The image on the right demonstrates the anatomy between the right ventricle (RV) and the aorta (Ao).

Heart failure symptoms include disproportionate, progressive fatigue, worsening shortness of breath with less and less activity, or difficulty breathing during sleep. Diagnostic imaging studies such as echocardiogram, cardiac magnetic resonance imaging (MRI), cardiac computed tomography scan, and angiography (cardiac catheterization) are used to track changes in heart size and function.

Surgical correction

Surgical corrections in CCTGA include VSD repair using patches or sutures to close the defect; placement of a tube graft to overcome left ventricle outflow tract obstruction (pulmonary muscle or valvular obstruction), and tricuspid valve repair or replacement for severe tricuspid valvular leakiness.

Pregnancy

Patients with CCTGA can successfully undergo pregnancy and delivery. There is small increased risk of congenital heart disease in the fetus therefore; we recommend a fetal echocardiogram around 20-24 weeks gestation. All patients who are contemplating pregnancy should undergo a thorough evaluation prior to pregnancy.

Pregnancy and birth control. Some congenital heart defects are passed down through families. For this reason, you may want to seek genetic counseling to determine your risk for having a child with a heart defect. Pregnancy may increase certain health risks for women with heart defects, requiring close monitoring from experts in adult congenital heart disease and high risk maternal fetal clinicians. If you are trying to prevent pregnancy, you will need to select a form of birth control that poses the lowest risk to your health.

In most cases, the cause of a congenital heart defect is not known. However, certain things increase your baby's chances of developing a heart defect. A child's risk for having a congenital heart defect increases if a brother, sister, or parent has one. Children who have other genetic conditions such as Down syndrome have an increased risk for having a congenital heart defect. Babies born too early have a higher chance of having a congenital heart defect. Pregnant women or those who plan to become pregnant may be able to reduce their risk of having a baby with a congenital heart defect by taking steps to have a healthy pregnancy.

For a healthy pregnancy, avoid:

- Exposure to chemicals, such as to paints, varnishes, solvents, hair dyes, and glues
- Exposure to certain diseases, such as German measles (rubella). If you have never had rubella or been vaccinated for it, talk with your health professional about getting vaccinated before becoming pregnant
- Use of certain medicines, such as diazepam, corticosteroids, phenothiazines, and some gastrointestinal drugs.
- Cigarette smoking, tobacco, illegal drugs (including cocaine), alcohol
- Exposure to extremely cold temperatures and places where you may not get enough oxygen, such as being at high altitudes without extra oxygen
- An unborn baby (fetus) has a higher chance of developing a congenital heart defect when the mother has diabetes or phenylketonuria

Long term surveillance

- Follow visit with experts in Adult Congenital Heart Disease
- Resting EKG
- Measurement of oxygen saturation
- 24 hour Holter monitoring
- Imaging studies, for example, cardiac MRI, echocardiography, cardiac CT or angiography
- Exercise stress testing to assess functional capacity (VO2 stress testing)

Other considerations:

Employment Get an expert opinion from a cardiologist about your physical capabilities and risk for future heart problems as you explore career options. With this information, you can make realistic choices and get appropriate training. Also, recognize and be prepared for employers who may underestimate your physical capabilities. Even though no more than 10% of adults with congenital heart defects are considered disabled, some people may assume that all heart defects are serious and impair normal functioning.

Health insurance Be aware that people with congenital heart defects often have difficulties when trying to change health insurance or when applying for new coverage. Research your options carefully before changing policies and find out whether you may qualify for state or federal assistance programs.

Use of antibiotics Most people with congenital heart defects have a lifelong increased risk for endocarditis and need to take antibiotics before having certain dental and surgical procedures.

Exercise The majority of patients with CCTGA can be quite active and participate in aerobic type activity – walking, bike riding, jogging, and swimming. Patients should always avoid heavy lifting or any activity that involves isometrics - lifting, pulling, pushing, and activities that cause grunting or straining.
You need to talk to your doctor before getting involved in sports or exercising. You may need an exercise electrocardiogram (cardiac stress test), sometimes done along with a type of echocardiogram, to measure how your heart responds to exercise.